



<http://www.priory.com/psych.htm>

## **MRI changes in Cocaine induced Toxic encephalopathy**

Saravanan Balamuthusamy MD, MPH

Bindu Desai MD

**Abstract:** Toxic encephalopathies caused by cocaine have resulted in irreversible changes in the cerebral white matter. These changes usually take a few months to evolve. The changes tend to persist even after cessation of cocaine abuse. The neurological course varies in different patients and the reason why it differs is not known. We have presented a unique case with acute changes noted in T2 weighted images of the brain in a cocaine abuser.

**Key Points:**

- Cocaine abuse causes irreversible changes brain changes on MRI
- Cocaine induced toxic encephalopathy presents with neurobehavioral and MRI changes
- Cocaine causes decreased cerebral blood flow in about 50 % of abusers
- Prognosis is guarded in acute cocaine induced acute toxic encephalopathy

**Key Words:** encephalopathy, cocaine, MRI imaging, decreased cerebral blood flow

**MRI changes in Cocaine induced Toxic encephalopathy**

**Introduction:** Cocaine is known to cause decreased cerebral blood flow and ischemic white matter changes in more than 50% of the chronic abusers. MRI changes have been noticed in most of chronic abusers and tend to persist even after 6 months of sustained abstinence from cocaine.

There are no case reports that have shown acute changes in the MRI with progressive worsening of neurological function.

**Case Summary:**

A 42 year old male with no past history was brought to the ER after as he was found naked in a motel. Initially patient was alert and responsive. Two days later he was agitated and proceeded to become unresponsive. He was then transferred to the ICU and was administered thiamine, folate, narcane and flumazenil with transitory improvement in responsiveness. Patient was then re-transferred to the medical floor. Labs done at the ER Na: 141 K: 4.3 Cl: 109 HCO<sub>3</sub>: 22 Cr: 0.8 BUN: 12 WBC: 17.2 HCT: 35.8 HGB: 11.8 Plt: 376 .The labs were unremarkable except that urine drug screen was positive for cocaine. Patient had a history of snorting heroin.

Physical examination at the time of transfer from ICU: patient was not responsive to verbal stimuli, pupils were reactive equally, and no evidence of trauma, corneal reflex was present bilaterally. Tone was decreased in all extremities, deep tendon reflexes were 1+ with extensor

plantar response bilaterally. Patient did not move limbs to pain; he appeared to stare at space.

MRI images done on day 8 of admission revealed no significant enhancement. EEG revealed diffuse slowing of the background compatible with a disorder of a diffuse nature metabolic, degenerative or infectious.

Lumbar puncture: CSF glucose: 56, protein 53, gram stain and cultures were normal, WBC 1.

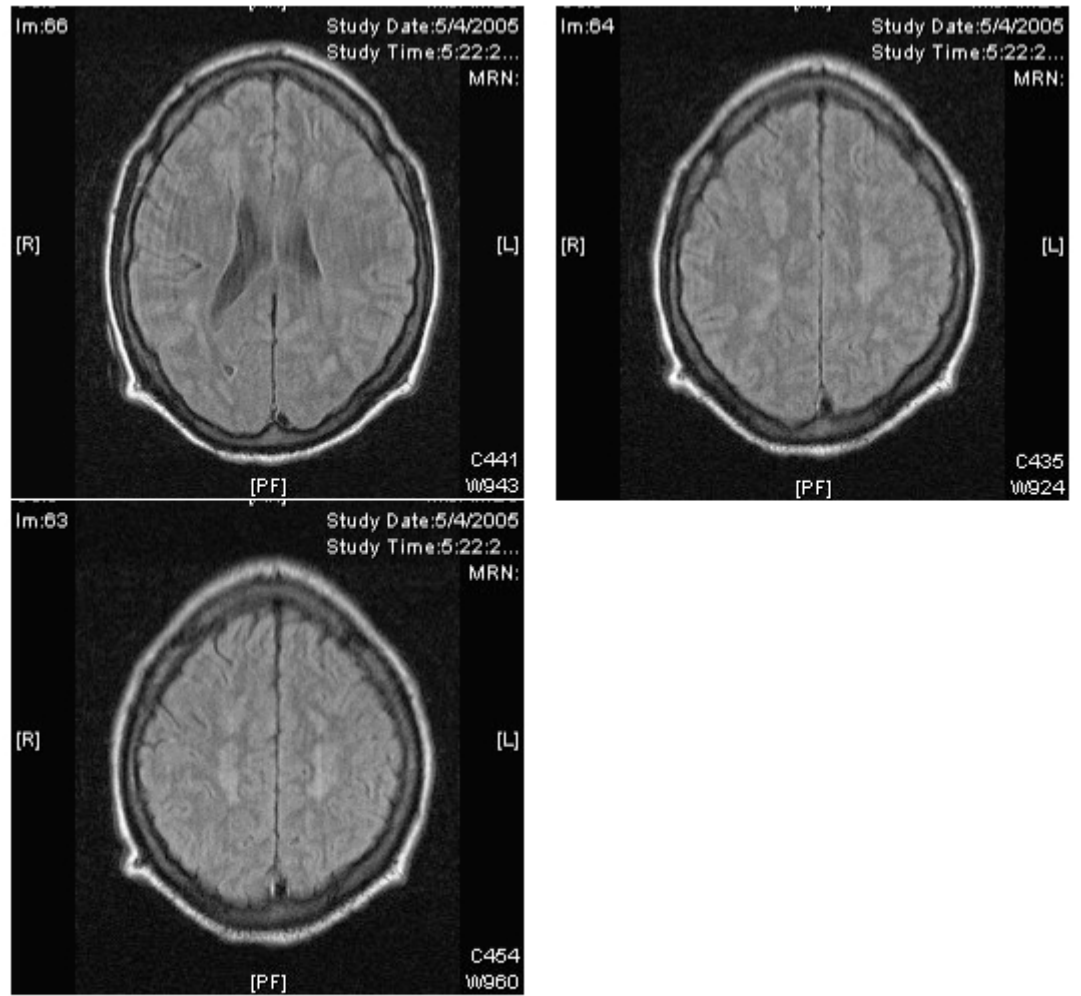


Figure 1

MRI images done on day 8 of admission reveals no significant enhancement.

As the patient did not become alert and responsive a repeat MRI was done on day 16 of admission which revealed significant enhancement changes in the white matter on T2 weighted images. Feeding was initiated with PEG tube.

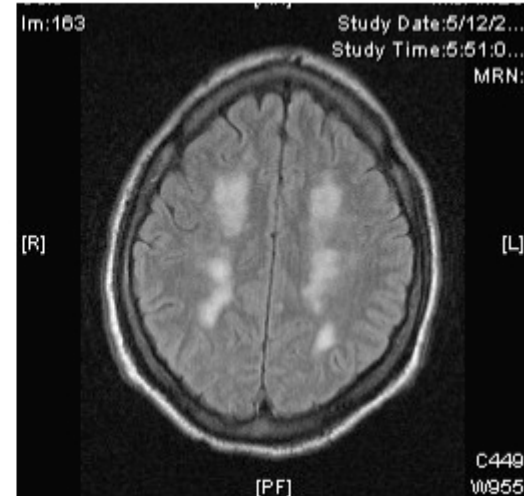
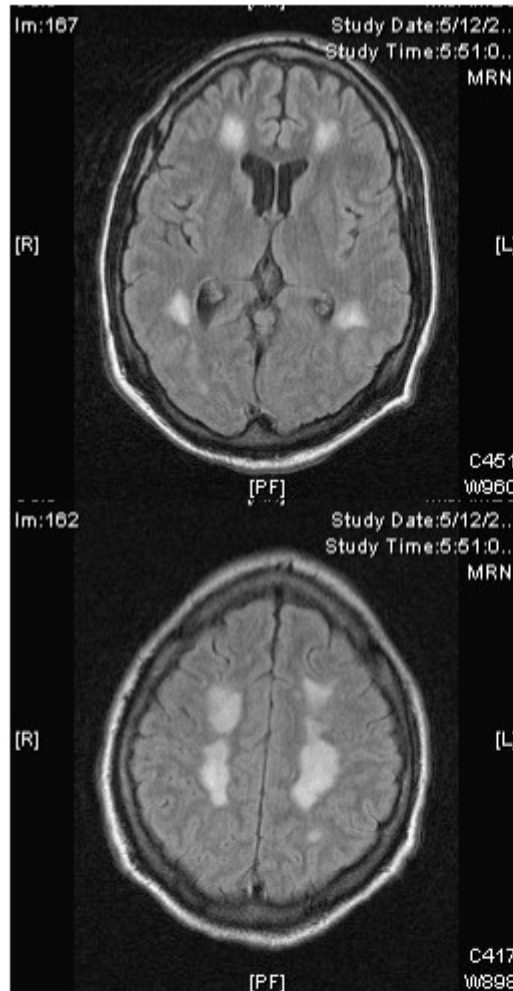


Figure 2:

MRI done on day 16 reveals significant enhancement changes on T2 weighted images.

**Diagnosis:** Cocaine induced toxic encephalopathy

**Discussion:**

Leukoencephalopathies are structural alterations in brain white matter in which myelin suffers the most damage. It is seen in patients exposed to toxins who reveal neurobehavioral disturbances after exposure to toxins. MRI

has enabled better recognition of these disorders. Even asymptomatic cocaine abusers have been found to have significant white matter lesions on MRI when compared to control population. Cocaine abusers are at increased risk of ischemic insults to the white matter.(1).T2-Weighted MR imaging has revealed imaging signal abnormalities in the brain of cocaine abusers. Cocaine can cause varying levels of brain damage. Vasospasm with or without intravascular thrombosis are the proposed mechanisms of cocaine induced neurotoxicity (2). Studies have shown 25 to 30% decrease in cerebral blood flow in cocaine abusers (3). There are also records of perfusion defects in nearly 70% of cocaine abusers that persist even after 6 months of continued abstinence (4, 5, 6).The patient presented above had normal MRI images 8 days after admission, but developed hyperintensities in the T2 –Weighted images done two weeks days after admission. The most likely explanation is the formation of longer half life vasoactive metabolites( 7,8,) of cocaine which can contribute to delayed ischemic symptoms that are seen as hyperintense lesions in the MRI (9,10).

Our patient developed complicated urinary tract infection with severe sepsis, got transferred to the ICU and then expired due to septic shock.


**Conclusion:** Hyperintensities in the periventricular white matter have been noted in chronic cocaine abusers and they tend to persist even after abstinence. There can also be development of acute hyperintensities during an attack of cocaine induced toxic encephalopathy in 7 days as reported in our case where the prognosis is very guarded and the possibilities of retaining consciousness are remote.

**References:**

1. Toxic Encephalopathy; Review article NEJM, Vol. 345, No.6. August 9, 2001.
2. American Journal of Neuroradiology 20: 1628-1635 (10 1999)
3. Cocaine induced cerebral vasospasm in Humans. Detection with MRA. Kaufman MJ, Levin JM, Ross M, et al
4. Cerebral blood flow in chronic cocaine users. A Study with PET. British Journal Of Psychiatry 1988; 152:641-648



5. Cerebral abnormalities in cocaine abusers. Demonstration by SPECT perfusion scintigraphy. Radiology 1990; 176:821-824
6. Cerebral perfusion and neuropsychological consequences of chronic cocaine use. Journal of neuropsychiatry clinical neuroscience 1993;5:419-427
7. Cocaine and benzoylecgonine constrict cerebral arteries by different mechanisms. Life science 1995;56: 679-686
8. Cytotoxicity of the cocaine metabolite benzoylecgonine Brain research 1994;634: 108-114
9. The neurovascular complications of cocaine .Surgical Neurology 1997;47: 339-345
10. Cerebrovascular complications of the use of crack cocaine. NEJM 1990;323: 699-704



<http://www.priory.com/psych.htm>

Published October 2005

Saravanan Balamuthusamy MD, MPH

Bindu Desai MD

Department of Medicine and Neurology

Chicago Medical School at Rosalind Franklin University

Chicago, Illinois

Corresponding Author:

Saravanan Balamuthusamy

Mount Sinai Medical Center

15<sup>th</sup> street at California ave

Chicago-IL-60130

Ph : 773-257-1286

Fax : 847 578-6436